

The management of cubitus varus and valgus using the Ilizarov method

A. Piskin,
Y. Tomak,
C. Sen,
L. Tomak

From Ondokuz
Mayis University,
Samsun, Turkey

Cubitus varus and valgus are the most common complications of supracondylar and lateral condylar fractures. Various combinations of osteotomy and fixation have been described to correct these deformities but each is associated with significant complications. In this study, we used distraction osteogenesis and Ilizarov frame fixation to treat 24 elbows in 23 patients with cubitus varus or valgus. Their clinical outcome was evaluated using the protocol of Bellemore et al. The mean time to follow-up was 18.3 months (10 to 36) and the mean time to frame removal was 13.5 weeks (8 to 20). The mean carrying angle was corrected from -18.7° (-10° to -30°) to 6.1° (2° to 10°) in patients with cubitus varus and from 36.5° (25° to 45°) to 9.4° (4° to 15°) in patients with cubitus valgus. There were 18 excellent and six good results.

The Ilizarov method with gradual distraction is a safe, stable, adjustable and versatile method of treating deformities at the elbow without the problems of an unsightly scar or limited range of movement, and gives a good clinical and radiological outcome. Tardy ulnar nerve palsy should be treated first by anterior transposition.

Supracondylar fractures of the humerus comprise approximately 10% of all paediatric fractures and, with fractures of the lateral condyle, are the most common fractures of the elbow in children.¹⁻⁶ Malunion results in cubitus valgus or cubitus varus. Many types of osteotomy and fixation have been described to correct these deformities.^{5,7-17} Most, however, are associated with well recognised technical problems and significant complications.^{9,11-13,17} These include under- or over-correction, failure of fixation, neuropraxia, an unsightly scar, refracture at the osteotomy site, limitation of range of movement (ROM) at the elbow, infection and nerve injury.

We have used the Ilizarov method of distraction osteogenesis and frame fixation for the treatment of the patients with cubitus varus and valgus.¹⁸ This is only the third paper in the literature reporting Ilizarov external fixation for deformities of the elbow.⁷⁻¹¹ It differs from the others by applying the principles of deformity correction described by Paley.¹⁹

Patients and Methods

We treated 24 elbows in 23 patients by osteotomy and gradual correction using the Ilizarov method. There was cubitus valgus in 13 elbows and cubitus varus in 11. One patient

had a cubitus varus on the right side and a cubitus valgus on the left and required bilateral operations. There were 16 boys and seven girls with a mean age of 12.4 years (8 to 18). Cubitus varus was the result of a supracondylar fracture in each case. Cubitus valgus occurred after a fracture of the lateral condyle in eight of the 13 patients and after a supracondylar fracture in the other five. Seven patients with cubitus valgus had a tardy ulnar nerve palsy. Two were left untreated while the other five had an anterior transposition of the ulnar nerve just before their frame was applied.

Surgical technique. The operation is carried out with the patient supine and the affected arm on a radiolucent arm table. There is no need for a tourniquet. We regard the main deformity in cubitus varus and valgus as being in the coronal plane.

The pre-operative planning is carried out as follows: first, the joint line is marked on the radiograph. Next, a line is drawn at an angle of 6° to 8° to establish the normal valgus angle of the elbow (the valgus inclination line/angle). A line perpendicular to this is constructed (the distal vertical line) which crosses the anatomical axis of the humerus at the centre of rotation of angulation. A line bisecting the obtuse angle of this intersect represents the line of osteotomy.

■ A. Piskin, MD, Orthopaedic Surgeon, Assistant Professor
■ Y. Tomak, MD, Orthopaedic Surgeon, Associate Professor
Department of Orthopaedic Surgery
■ L. Tomak, MD, Assistant Professor
Department of Biostatistics
Ondokuz Mayis University,
Faculty of Medicine, 55139
Kurupelit, Samsun, Turkey.

■ C. Sen, MD, Orthopaedic Surgeon, Associate Professor
Department of Orthopaedic Surgery
Gazi Osman Pasa University,
Faculty of Medicine, 60100
Tokat, Turkey.

Correspondence should be sent to Professor Y. Tomak; e-mail: ytomak@hotmail.com

©2007 British Editorial Society of Bone and Joint Surgery
doi:10.1302/0301-620X.89B12.19361 \$2.00

J Bone Joint Surg [Br]
2007;89-B:1615-19.

Received 26 February 2007;
Accepted after revision 30 July 2007

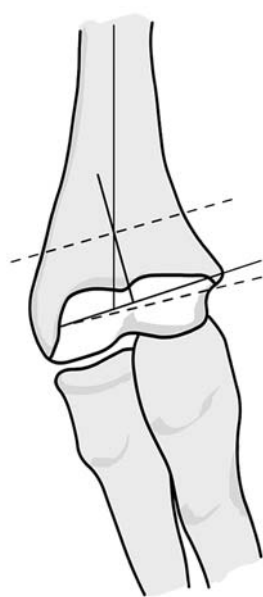


Fig. 1a

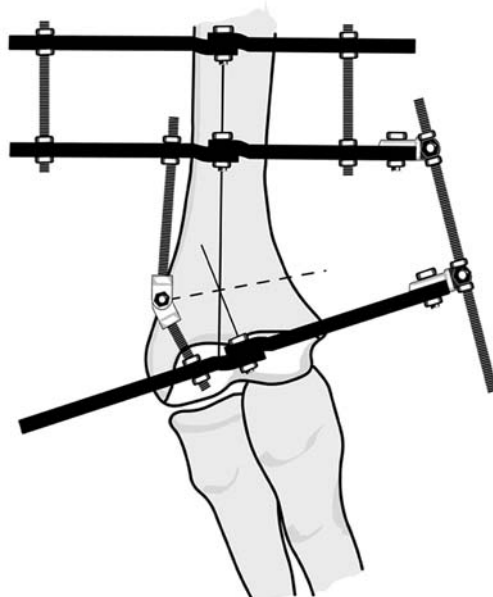


Fig. 1b

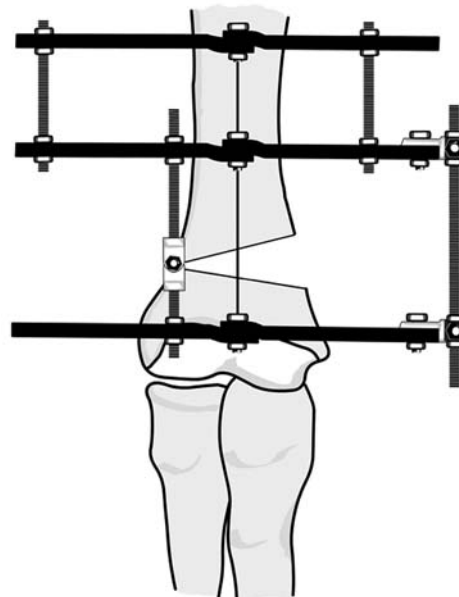


Fig. 1c

Diagrams showing the Ilizarov method of fixation for cubitus varus. a) The pre-operative plan. The most distal dotted line is the joint line. The valgus inclination line is set at 6° to 8° to the joint line in the coronal plane. The line perpendicular to this is the axis of the humerus at the centre of rotation of angulation. The upper dotted line bisects the obtuse angle of this intersect and represents the line of osteotomy. b) The humeral frame. The lower humeral obtuse angle formed is at the level of the valgus inclination line, and the upper humeral ring at the level of the middle third of the diaphysis. c) The hinge is at the level of the bisector line and lies over the lateral bisector line osteotomy opened cortex around the centre of rotation of angulation, thereby correcting the deformity.

The first (distal reference) wire is inserted from the posterolateral aspect of the lateral condyle and is passed to the anterior cortex of the medial epicondyle at 6° to 8° valgus inclination to the joint line. The second wire is inserted from the posteromedial aspect of the medial epicondyle and passed to the anterior cortex of the lateral condyle. These two wires should be olive-tipped to avoid translation of the distal full circle. A half pin is introduced from the posterolateral aspect of the lateral condyle to strengthen the fixation. A second full circle is then applied approximately 4.0 cm to 5.0 cm above the apex of the deformity using a smooth wire and a half pin. The hinge is assembled and positioned at the level of the apex of the deformity. A motor unit is then placed on the concave aspect of the frame at 90° to the axis of the hinges. The hinge at the line of osteotomy on the convex side of the deformity is aligned with the centre of rotation of angulation. An opening wedge correction is achieved without any translation, shortening or lengthening (Figs 1 and 2). A third full circle can be applied as necessary above the second in the same manner. All the wires and half pins are inserted under image intensification. After applying the frame, a small incision is made over the apex of the deformity, and two small blunt Hohmann retractors (Bahadir, Samsun, Turkey) placed for subperiosteal exposure of the osteotomy line. After carrying out the osteotomy, all the

clamps and nuts are re-tightened and the final position checked with the image intensifier.

Post-operatively, all pin sites are cleaned meticulously with antiseptic until any serious drainage had stopped. We use hydrogen peroxide to clean away any scab or clot present around the pins.

In our patients, elbow and shoulder exercises were started on the first post-operative day. Distraction was started after seven days and took place four times each day ($2\text{ mm} \times 1.0\text{ mm}$ and $2\text{ mm} \times 0.5\text{ mm}$, a total of 3.0 mm per day). A 3.0 mm distraction at the motor unit is approximately equal to 1.0 mm distraction at the osteotomy site. Distraction was continued until full correction of the deformity had been achieved. The hinges and the motor unit were then removed and the full circles connected with rods. The anterior third of the distal full circle was cut with a Gigli saw to allow full flexion of the elbow (Fig. 3). A radiograph was taken at this stage and then subsequently at 14-day intervals. Once radiological union had been achieved, the frame was removed in the out-patient department.

The results were evaluated according to the system of Barrat, Bellemore and Kwon.²⁰ A carrying angle of $\leq 5^\circ$ and limitation of flexion and extension by $\leq 10^\circ$ was considered an excellent outcome. A carrying angle of 6° to 10° and limitation of flexion and extension by $\leq 20^\circ$ was con-

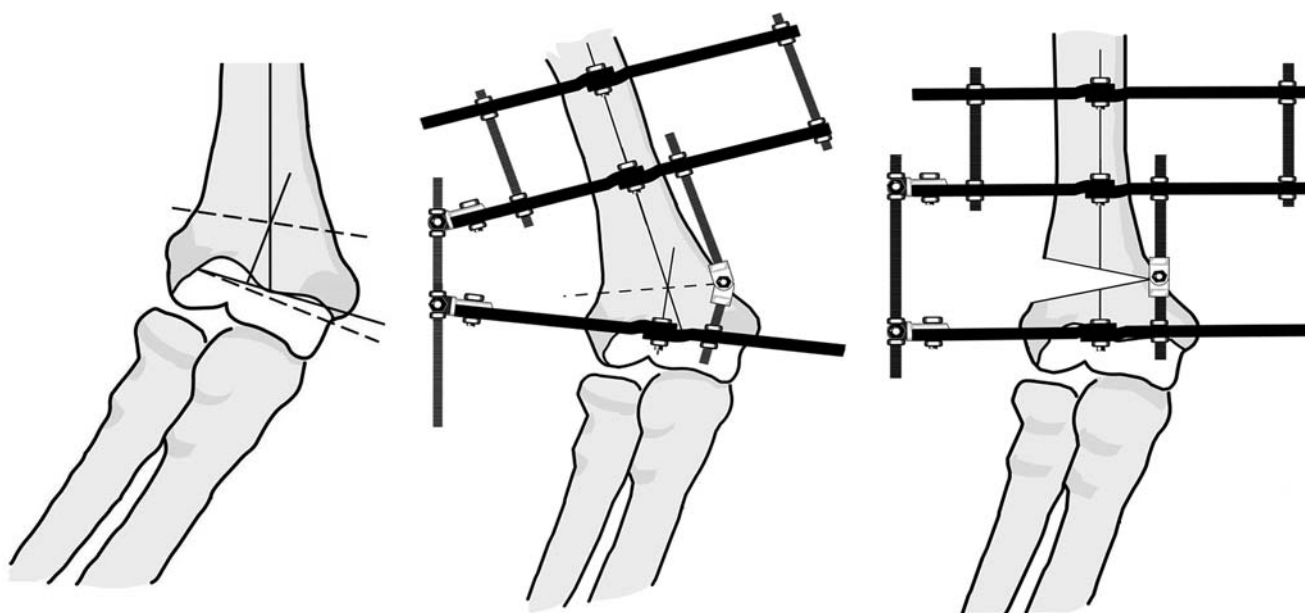


Fig. 2a

Fig. 2b

Fig. 2c

Diagrams showing the Ilizarov method of fixation for cubitus valgus. a) The pre-operative plan. The most distal dotted line is the joint line. The valgus inclination line is set at 6° to 8° to the joint line in the coronal plane. The line perpendicular to this is the axis of the humerus of the centre of rotation of angulation. The upper dotted line bisects the obtuse angle of this intersect and represents the line of osteotomy. b) The humeral frame. The lower humeral angle formed is at the level of the valgus inclination line, and the upper humeral ring at the level of the middle third of the diaphysis. c) The hinge is at the level of the bisector line and lies over the medial bisector line osteotomy opened cortex around the centre of rotation of angulation, thereby correcting the deformity.

sidered a good outcome and a carrying angle of $> 10^\circ$ and loss of flexion and extension of $\geq 20^\circ$ was considered to be a poor outcome.

Results

The mean period of follow-up was 18.3 months (10 to 36). The mean time to removal of the frame was 13.5 weeks (8 to 20). All patients had an excellent (18 elbows) or good (six elbows) outcome (Fig. 4). The mean pre-operative carrying angle of the patients with cubitus varus was -18.7° (-10° to -30°). The mean carrying angle at the last follow-up was 6.1° (2° to 10°). The mean pre-operative carrying angle of patients with cubitus valgus was 36.5° (25° to 45°). The mean carrying angle at the last follow-up was 9.4° (4° to 15°). The two patients with tardy ulnar nerve palsies, who did not undergo a transposition procedure had a persistent ulnar nerve palsy despite successful correction of the deformity.

Superficial pin-track infections occurred in five patients. These were treated with oral antibiotics and daily antiseptic dressings without any further problem. Three patients had 20° loss of flexion or extension without any loss of function. Lateral prominence was present in three of 11 patients with cubitus varus. Despite their normal function, we reported them as having a good rather than excellent result. No other complications were identified during the intra- and post-operative period.

Discussion

Since Siris²¹ first described a lateral closing wedge osteotomy for the correction of cubitus varus, many other techniques, such as medial closing wedge osteotomy, French osteotomy, dome osteotomy, arch osteotomy and pentalateral osteotomy, have been proposed.^{2,5,8,10,12,13} However, each of these has its drawbacks. Since most techniques achieve a definitive correction in one stage, further adjustment of the osteotomy is not possible even if needed. Poor results have been reported in up to 30% of cases because of loss of correction or failure to achieve an accurate initial correction.^{5,6} The anatomy of the supracondylar region makes it difficult to maintain the correction of any deformity by internal fixation with Kirschner wires, staples, or plates and screws,^{4,9,11} whereas the wires and half pins used with the Ilizarov method allow a secure fixation.

Song et al¹¹ described the use of the Ilizarov external fixator in the treatment of 15 adult patients with cubitus varus or valgus. In some cases, they had to shorten the humerus and trim the proximal fragment to improve bone contact. We would regard this as using an Ilizarov frame, rather than the Ilizarov method, in the absence of distraction osteogenesis.

Karatosun et al⁷ reported seven children with post-traumatic cubitus varus deformities who were treated by distraction osteogenesis with the Ilizarov method. They

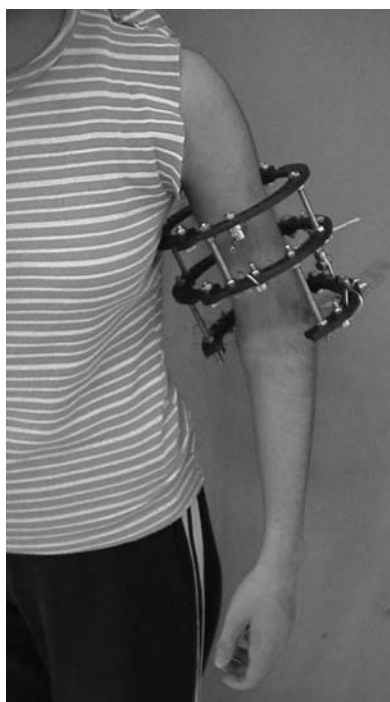


Fig. 3

Photograph showing the clinical appearance of a 16-year-old female with the Ilizarov frame in place. The anterior one third portion of the distal full circle has been cut to allow full flexion of the elbow.

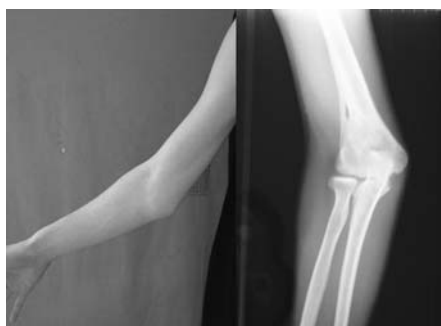

Fig. 4a

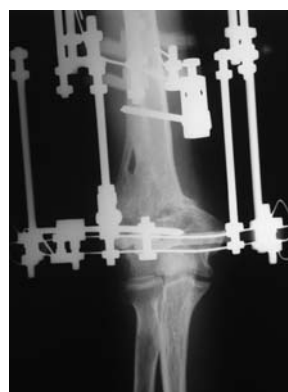

Fig. 4b

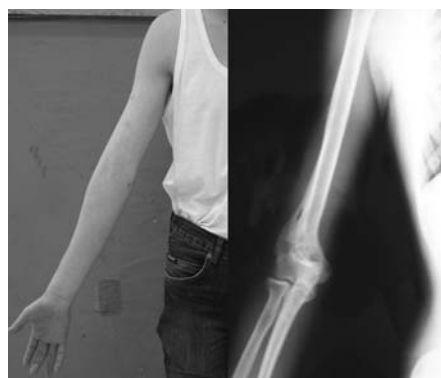

Fig. 4c

An 18-year-old male with cubitus valgus; a) pre-operative clinical appearance and anteroposterior radiograph of the deformity. The carrying angle was 36°, b) anteroposterior radiograph demonstrating correction of the deformity at the end of distraction period. Note the lateral opening wedge correction, and c) post-operative clinical appearance and anteroposterior radiograph of the right elbow with complete consolidation and an excellent cosmetic result. The carrying angle is 7°.

reported excellent results clinically and radiologically in every patient. They calculated their correction according to the method described by Herzenberg and Waanders.²²

In our study, we have based our prospective planning on the principles of deformity correction described by Paley.¹⁹ We did not transpose the ulnar nerve in the first two patients with tardy ulnar palsies and they failed to recover after correction of the cubitus valgus. Subsequently, we carried out a transposition routinely. Kim and Lee² have also noted that correction of the deformity alone is inadequate treatment for a tardy ulnar nerve palsy. Acute correction of the deformity can cause a traction injury of the ulnar nerve. Our osteotomy and gradual correction procedure did not worsen a pre-existing tardy ulnar palsy and did not cause any additional neurological problems.

Several authors have reported hypertrophic scars.^{4,7,9} We did not encounter this presumably because of the short incision required.

Prominence of the lateral condyle may be troublesome.^{2,4,9} In our series, it occurred in three patients (13%). It can be avoided by the medial translation of the distal fragment. Initially, we intended to correct only the deformity in the coronal plane. However, the deformity is usually three dimensional and the Ilizarov method allows for its com-

plete correction in angulation, translation, and rotation. In later cases, we started by correcting the deformity in the coronal plane then, if needed, we removed the hinges, and applied the rotation-translation devices of Paley.¹⁹ After correcting all planes of the deformity, these were removed


and the rings connected using a combination of rods and plates.

The gradual correction of cubitus varus or valgus by distraction osteogenesis has other advantages. The position of the distal fragment can be adjusted in all planes until complete consolidation has occurred. Stable fixation is possible even if there is no contact between the bony fragments. The elbow does not become stiff because the patients can start their exercises immediately. Consolidation of the osteotomy site is seen early, and the frame can be removed in out-patients.

As a result of our experience with this technique we can make a number of recommendations: first, any patient with a tardy ulnar nerve palsy should have this treated prior to corrective osteotomy; secondly, at the end of the distraction period, upper limb alignment must be carefully evaluated both clinically and radiologically. Any additional deformity, should be corrected at this stage; thirdly, it is essential that the patient is carefully assessed during the consolidation period. The use of carbon-fibre rings will make the radiological assessment of the patient much easier; finally, many of our patients are teenagers but we have also had similarly successful results in a small number of adult patients.

In conclusion, the treatment of deformities of the elbow by distraction osteogenesis with an Ilizarov method appears to be an efficient, safe, stable and versatile method which avoids unsightly scar formation and loss of range of movement. It offers some advantages such as the possibility of further correction during the distraction period and it allows the early resumption of daily activities. The frame can be removed without the need for a further anaesthetic.

Supplementary Material

 A table showing details of the study group and the results of the treatment is available with the electronic version of this article on our website at www.jbjs.org.uk

The authors would like to thank C. Genc for Figures 1 and 2.

No benefits in any form have been received or will be received from a commercial party related directly or indirectly to the subject of this article.

References

1. Wilkins KE, Beaty JH, Chambers HG, Toniolo RM. Fractures and dislocations of the elbow region. In: Rockwood CA Jr, Wilkins KE, Beaty JH, eds. *Fractures in children*. Fourth ed. Vol. 3. Philadelphia: LippincottRaven Publishers, 1996:653-904.

2. Kim HT, Lee JS, Yoo CI. Management of cubitus varus and valgus. *J Bone Joint Surg [Am]* 2005;87-A:771-80.
3. Gaddy BC, Manske PR, Pruitt DL, Schoenecker PL, Rouse AM. Distal humeral osteotomy for correction of posttraumatic cubitus varus. *J Pediatr Orthop* 1994;14:214-19.
4. Hasler CC. Correction of malunion after pediatric supracondylar elbow fractures: closing wedge osteotomy and external fixation. *Eur J Traum* 2003;5:309-15.
5. Oppenheim WL, Clader TJ, Smith C, Bayer M. Supracondylar humeral osteotomy or traumatic childhood cubitus varus deformity. *Clin Orthop* 1984;188:34-9.
6. Labelle H, Bunnell WP, Duhaime M, Poitras B. Cubitus varus deformity following supracondylar fractures of the humerus in children. *J Pediatr Orthop* 1982;2:539-46.
7. Karatosun V, Alekberov C, Alici E, Ardic CO, Aksu G. Treatment of cubitus varus using the Ilizarov technique of distraction osteogenesis. *J Bone Joint Surg [Br]* 2000;82-B:1030-3.
8. Kumar K, Sharma VK, Sharma R, Maffulli N. Correction of cubitus varus by French or dome osteotomy: a comparative study. *J Trauma* 2000;49:717-21.
9. Levine MJ, Horn BD, Pizzutillo PD. Treatment of posttraumatic cubitus varus in the pediatric population with humeral osteotomy and external fixation. *J Pediatr Orthop* 1996;16:597-601.
10. Matsushita T, Nagano A. Arc osteotomy of the humerus to correct cubitus varus. *Clin Orthop* 1997;336:111-15.
11. Song HR, Cho SH, Jeong ST, Park YJ, Koo KH. Supracondylar osteotomy with Ilizarov fixation for elbow deformities in adults. *J Bone Joint Surg [Br]* 1997;79-B:748-52.
12. Tien YC, Chih HW, Lin T, Lin SY. Dome corrective osteotomy for cubitus varus deformity. *Clin Orthop* 2000;380:158-66.
13. Voss FR, Kasser JR, Trepman E, Simmons E Jr, Hall JE. Uniplanar supracondylar humeral osteotomy with preset Kirschner wires for posttraumatic cubitus varus. *J Pediatr Orthop* 1994;14:471-8.
14. Mahaisavariya B, Laupattarakasem W. Osteotomy for cubitus varus: a simple technique in 10 children. *Acta Orthop Scand* 1996;67:60-2.
15. Danielsson LG, Hussain S, El-Haddad I, Gupta RP. Stable fixation of osteotomy for cubitus varus: a simple technique used in 11 children. *Acta Orthop Scand* 1991;62:55-7.
16. Laupattarakasem W, Mahaisavariya B, Kowsuwon W, Saengnipanthkul S. Pentalateral osteotomy for cubitus varus: clinica; experiences of a new technique. *J Bone Joint Surg [Br]* 1989;71-B:667-70.
17. Uchida Y, Ogata K, Sugioka YA. A new three-dimensional osteotomy for cubitus varus deformity after supracondylar fracture of the humerus in children. *J Pediatr Orthop* 1991;11:327-31.
18. Ilizarov GA. Clinical application of the tension-stress effect for limb lengthening. *Clin Orthop* 1990;250:8-26.
19. Paley D. Osteotomy concepts and frontal plane realignment. In: Paley D. *Principles of deformity correction*. First ed. Berlin: Springer-Verlag, 2002:99-154.
20. Barratt IR, Bellemore MC, Kwon YM. Cosmetic results of supracondylar osteotomy for correction of cubitus varus. *J Pediatr Orthop* 1998;18:445-7.
21. Siris IE. Supracondylar fracture of the humerus. *Surg Gynecol Obstet* 1939;68:201-22.
22. Herzenberg JE, Waanders NA. Calculating rate and duration of distraction for deformity correction with the Ilizarov technique. *Orthop Clin North Am* 1991;22:601-11.