

Supplementary material

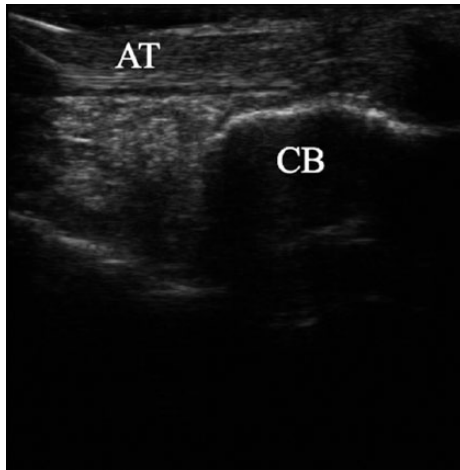


Fig. a

Photo taken prior to the ultrasound-guided injection procedure (retrocalcaneal bursa is empty) (CB, calcaneal bone; AT, Achilles tendon).

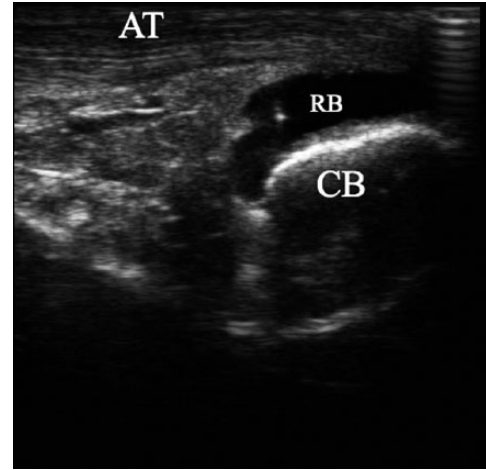


Fig. b

Photo taken after the procedure of ultrasound-guided injection of dye into the retrocalcaneal bursa (the needle can be seen as the hyperechoic point within the hypoechoic retrocalcaneal bursa filled with dye) (CB, calcaneal bone; AT, Achilles tendon; RB, retrocalcaneal bursa).